

# Psychodynamic Aspects in an Indonesian Adolescent with Anorexia Nervosa: A Case Report

Andrian Fajar Kusumadewi<sup>1\*</sup>, Wahyu Tri Soenaryanti<sup>2</sup>, Ananti Wungudita<sup>3</sup>, Nadia Rosmalia Dewi<sup>3</sup>, Teresa Lalita Wiryarini<sup>3</sup>, Imtinanda Khalisa Amani<sup>3</sup>, Ilma Naafisha Anthrasita<sup>3</sup>, Risma Widiastuti<sup>3</sup>, Redita Aulia Fauziyya<sup>3</sup>, Veronica Destia Ramadhani<sup>3</sup>

## ABSTRACT

**Background:** Anorexia nervosa (AN) is a severe eating disorder characterized by extreme dietary restriction, fear of weight gain, and distorted body image. In Indonesia, research on AN is still limited and no case reports have yet documented its presentation, particularly from a psychodynamic perspective. Applying a psychodynamic framework, this paper seeks to uncover unconscious conflicts and internal dynamics that may underlie symptom formation, thereby offering a complementary perspective for the management of AN. **Case:** We report the case of a 15-year-old Indonesian female who experienced profound weight loss, from 76 kg to 27 kg. During hospitalization, psychiatric evaluation confirmed a diagnosis of restricting-type anorexia nervosa accompanied by a moderate depressive episode. The patient's condition was further complicated by depressive symptoms, including suicidal threats and social withdrawal. Within nine months after discharge, she required rehospitalization following a partial relapse. **Discussion:** This case report describes an adolescent girl with restricting-type AN and comorbid depression who experienced severe weight loss and partial relapse. Disordered eating, excessive exercise, low self-esteem, and body image disturbance were prominent. Treatment involved family-based therapy, cognitive behavioral therapy, and antidepressants. Psychodynamic factors, including perfectionism, external validation, and family dynamics, contributed to illness persistence. Sociocultural influences such as body shaming and thin-ideal internalization further increased vulnerability and relapse risk. **Conclusion:** This report therefore aims to examine the patient's psychodynamic profile, with particular attention to how emotional conflicts, unconscious processes, and relational patterns may have contributed to the onset and course of the disorder.

**Keywords:** Anorexia nervosa, adolescent, psychodynamic, eating disorder

1. Department of Psychiatry, Faculty of Medicine, Public Health, and Nursing, Universitas Gadjah Mada, Indonesia
2. Psychiatric Resident of Department of Psychiatry, Faculty of Medicine, Public Health, and Nursing, Universitas Gadjah Mada, Indonesia
3. Research Assistant of Department of Psychiatry, Faculty of Medicine, Public Health, and Nursing, Universitas Gadjah Mada, Indonesia

\* ✉ email: andrian.fajar.k@ugm.ac.id

## INTRODUCTION

Anorexia nervosa (AN) is a complex eating disorder (ED) characterized by severe dietary restriction, an intense fear of gaining weight, and a distorted body image<sup>1</sup>. It primarily affects adolescents and young adults, with adolescent females being particularly vulnerable<sup>2</sup>. The disorder has significant physical, psychological, and social consequences and typically requires a multifaceted treatment approach<sup>3</sup>.

An epidemiological study by Liu et al<sup>4</sup> reported a marked increase in the global burden of eating disorders (AN and Bulimia Nervosa) among adolescents and young adults. In Southeast Asia specifically, the age-standardized prevalence rate was found to be 81.7 per 100,000 population in 2021, with an estimated annual increase of 0.65% since 1990. Lack of awareness, insufficient coverage of mental health resources, and stigma attached to eating disorders in the region may contribute to underdiagnosis<sup>5</sup>.

However, in Indonesia, research on anorexia nervosa is still limited and epidemiological data remain unavailable. A regional study by Tantiani and Syafiq<sup>6</sup> reported a high prevalence of eating disorders among middle- and high-school students with an overall prevalence of 37.3%, including 11.6% for anorexia nervosa and 27% for bulimia nervosa. Additionally, 26.1% of adolescent girls were at risk of developing eating disorders (EDs)<sup>7</sup>. These findings underscore the need for increased attention to EDs, particularly among adolescents, within Indonesia's healthcare system.

Given the limited research and the substantial prevalence of eating disorders among Indonesian adolescents, a comprehensive understanding of anorexia nervosa is crucial. Beyond clinical management, examining the disorder through a psychodynamic lens can provide valuable insights into the deeper psychological processes involved.

The psychodynamic aspects explored in this case are intended to enhance understanding of underlying emotional conflicts, unconscious motivations, and relational patterns that may contribute to the onset and maintenance of the disorder. This approach aims to provide insight into how early life experiences, family dynamics, and self-perception interact to shape the individual's relationship with food, body image, and sense of self. Accordingly, this study examines the psychodynamic aspects of an adolescent patient with anorexia nervosa and situates the findings within the broader Indonesian sociocultural context.

## CASE

### *Prior to First Admission*

We report a 15-year-old female patient, diagnosed with restricting-type anorexia nervosa in a depressive episode. The patient was socially and academically bright, engaged in extracurricular activities, including modeling, where she won a competition in elementary school. The patient had always been an overweight but cheerful child. No significant previous psychiatric or medical history was reported.

The patient, weighing 76 kg, began efforts to lose weight 1.5 years prior to hospitalization, influenced by remarks from her father regarding her weight and witnessing peer bullying. She began reducing food portions and following an unassisted online exercise program, while maintaining normal social and academic activities. She adopted a highly restrictive, low-calorie, low-fat, high-protein diet in addition to an intense weightlifting routine. When pressured to eat by her mother, the patient once threatened suicide.

Three months prior to admission, the patient had lost 49 kg and stopped menstruating. She began presenting symptoms of weakness, dizziness, and unsteady gait. She remained preoccupied with weight loss and muscle gain, refusing professional nutritional advice. Upon

starting high school, a month before hospitalization, her obsessive diet and exercise further intensified, including additional physical activity during school hours.

#### *Psychiatric Evaluation*

Upon psychiatric evaluation, the patient appeared appropriate to their ages, with poor self-care, a thin appearance, and seeming somewhat weak. She displayed dysphoria, pain, and regressive behaviors, often requiring assistance with activities of daily living (ADLs). Her body mass index (BMI) was below 18 kg/m<sup>2</sup>, with a previous body weight of approximately 27 kg and a height ranging from 165 to 170 cm.

On her mental status examination, the patient was in a state of *compos mentis*. She was well oriented to person, time, place, and situation. Her attitude and behavior were characterized by hypoactivity, non-cooperativeness, and negativism, as evidenced by refusal to undergo examination. Speech was markedly limited, and the patient refused to communicate with medical personnel. Thought form appeared realistic, while thought content was dominated by preoccupation with body weight and restriction of food intake, accompanied by a strong desire to remain thin. No suspicious ideation was noted. The stream of thought appeared minimal, consistent with her limited speech.

Affect was dysphoric with tension, and the mood was also dysphoric. No hallucinations, illusions, or other perceptual disturbances were observed. Rapport was difficult to establish, and the patient's attention was difficult to engage and sustain at the beginning of the examination. Memory and cognitive functions were difficult to assess adequately. Insight was at grade 1, indicating denial of illness. Judgment appeared to be impaired.

Body image disturbance was present, as she expressed feelings of worthlessness and undesirability due to her "ugliness". She

appeared unaware of the abnormality of her condition. A graphic assessment (House-Tree-Person test) revealed depression, low self-esteem, anxiety, psychological trauma, and a need for recognition.

Alloanamnesis from both parents revealed that they had observed the patient's change in behavior ever since she started her rigorous diet and exercise routine. She became more irritable and socially withdrawn. The patient stated that she frequently experienced a depressed mood and feelings of worthlessness, with occasional episodes of crying. These symptoms, in addition to suicidal ideation and fatigue, fulfilled the DSM-5 diagnostic criteria for moderate depression.

Regression, splitting, idealization, and acting out were prominent defense mechanisms in this case. Regressive behaviors were especially observed during hospitalization. She required her father to hold her and accompany her to sleep. She wore children's pajamas and played with dolls. She referred to herself as "*dedek*" (meaning "young" or "little sibling") instead of standard first-person pronouns. She only allowed herself to eat hospital foods under specific conditions, such as on mental status examination the female appeared king around beforehand and receiving constant emotional reassurance from her father while being fed.

#### *Referral and Admission*

Concerned parents brought the patient to a dietitian for evaluation. In the last nutritional consultation, the patient presented with a weight of only 27 kg and was referred for further investigation. Upon referral, the patient appeared severely underweight (height: 155 cm; BMI: 11.2 kg/m<sup>2</sup>), with dry skin and prominent ribs. She was assessed with marasmic malnutrition secondary to restricting-type anorexia nervosa. The patient was admitted for nutritional rehabilitation and psychiatric intervention.

**Table 1.** Summary of pharmacotherapy, psychotherapy, clinical response, side effects, and follow-up by care phase

Phase / Time	Drug / Intervention	Dose	Goal	Side Effects / Notes	Therapeutic Response	Follow-up
Hospitalization I Aug-Sep 2024	Aripiprazole + Fluoxetine	—	AN restricting type + moderate depression	<b>STOP</b> AST/ALT sharply elevated; blood glucose disturbance → suspected drug-induced hepatotoxicity	Discontinued	Switched to olanzapine
Hospitalization I Aug-Sep 2024	Olanzapine	—	Mood stabilization + appetite stimulation	<b>WATCH</b> Significant appetite increase; AST/ALT normal	Good; weight gained; cooperativeness improved	Continued outpatient
Hospitalization I Aug-Sep 2024	CBT (~3 months, 2 sessions/week)	—	Cognitive restructuring, emotion regulation, body image	—	Cooperativeness increased; body image improved; returned to school	Continued outpatient
Hospitalization I Aug-Sep 2024	Family-Based Therapy (FBT)	—	Family involvement; parental support	—	Father more present; mother more empathic; patient motivation increased	Continued outpatient
Hospitalization I Aug-Sep 2024	Food journal/diary	—	Increase therapeutic engagement	—	Cooperativeness gradually increased	—
Outpatient I 26 Oct 2024	Olanzapine (continued)	—	Mood maintenance + appetite	<b>WATCH</b> Weight increased to ~70 kg; patient felt ashamed	Weight up; school activities resumed; anxious affect	Follow-up continued
Outpatient I 26 Nov 2024	Fluoxetine	30 mg, 1×0.25 after meals	Moderate depression; anxiety	—	Sadness & anxiety reduced; still without friends	Physiotherapy: swimming/cycling activities
Outpatient I 4 Jan 2025	Aripiprazole	10 mg, 1×0.5 as needed	Adjunct for depression	—	Anxiety reduced; more flexible about eating; persistent difficulty	Wt 60 kg, BMI 23.73
Lost to FU Feb-Apr 2025	<i>Patient did not attend psychiatric clinic – reportedly ashamed due to weight gain from olanzapine side effects. No structured psychiatric intervention during this period.</i>					
Hospitalization II 19 May 2025	Fluoxetine + Quetiapine	Fluoxetine 10 mg/24h PO morning; Quetiapine 100 mg/24h PO night	Partial relapse AN; moderate depression (CDI 23); suicidal ideation	—	Days 1–2: still dysphoric, difficulty sleeping, unwilling to talk much	Daily evaluation
Hospitalization II 21–22 May 2025	Fluoxetine + Aripiprazole + Lorazepam	Fluoxetine 10 mg; Aripiprazole 10 mg PO night; Lorazepam 1 mg PO night	Titration: agitation, insomnia, anxiety	<b>WATCH</b> Aripiprazole at night taken at 04:00 (poor adherence)	Days 3–4: able to eat a little; still sad; began to smile	Close monitoring
Hospitalization II 24–26 May 2025	Supportive psychotherapy + psychology consult	—	Social maladjustment; trauma from coach reprimand	—	Days 5–7: emotions stable, sleeping well, willing to eat more; discharged 26 May	Comorbid Dx: depression, bulimia, BDD; Insight 1→5
<b>Important clinical notes:</b> Olanzapine side effects (appetite increase → significant weight gain) were the main factor in <i>lost to follow-up</i> and contributed to relapse. Comorbid depression, bulimia nervosa, and body dysmorphic disorder were only identified during the second hospitalization, highlighting the need for comprehensive comorbidity assessment from the outset. Persistent social isolation (no friends, peer stigma) was unresolved across all treatment phases.						

Abbreviations: AN = anorexia nervosa; BDD = body dysmorphic disorder; BMI = body mass index; CBT = cognitive behavioral therapy; CDI = Child Depression Inventory; DC = discharge; FBT = family-based therapy; LFU = lost to follow-up.

### Treatment in this Case

The treatment plan incorporated pharmacological therapy with antidepressants, alongside cognitive behavioral therapy (CBT). The duration of CBT was approximately three months with sessions held every two weeks. The CBT content was tailored to the needs of adolescent girls, which included psychoeducation, problem-solving, emotion regulation, disputing cognitive distortions, and education on balanced nutrition.

Family involvement through Family-Based Therapy (FBT) was a critical aspect of her care. The father was encouraged to be more present and emotionally

supportive, while the mother received education on listening attentively to the patient’s needs without being judgmental. Positive reinforcement and physical affection from her parents were considered crucial for her treatment. The patient also received and acknowledged the care and support from teachers and schoolmates, which further encouraged her recovery. She expressed a desire to regain physical abilities for activities such as studying, praying, cooking, and exercising normally.

### Follow-ups

The patient’s clinical course demonstrates a fluctuating and non-linear trajectory of symptoms, global functioning,

and body weight from onset to partial relapse.

At onset, the patient presented with severe anxiety, restrictive eating behavior, and marked functional impairment (GAF 40–31), accompanied by significant underweight. During the first inpatient admission, there was gradual clinical improvement, followed by continued recovery in the outpatient phase, including weight restoration and partial remission of symptoms (GAF 70–61).

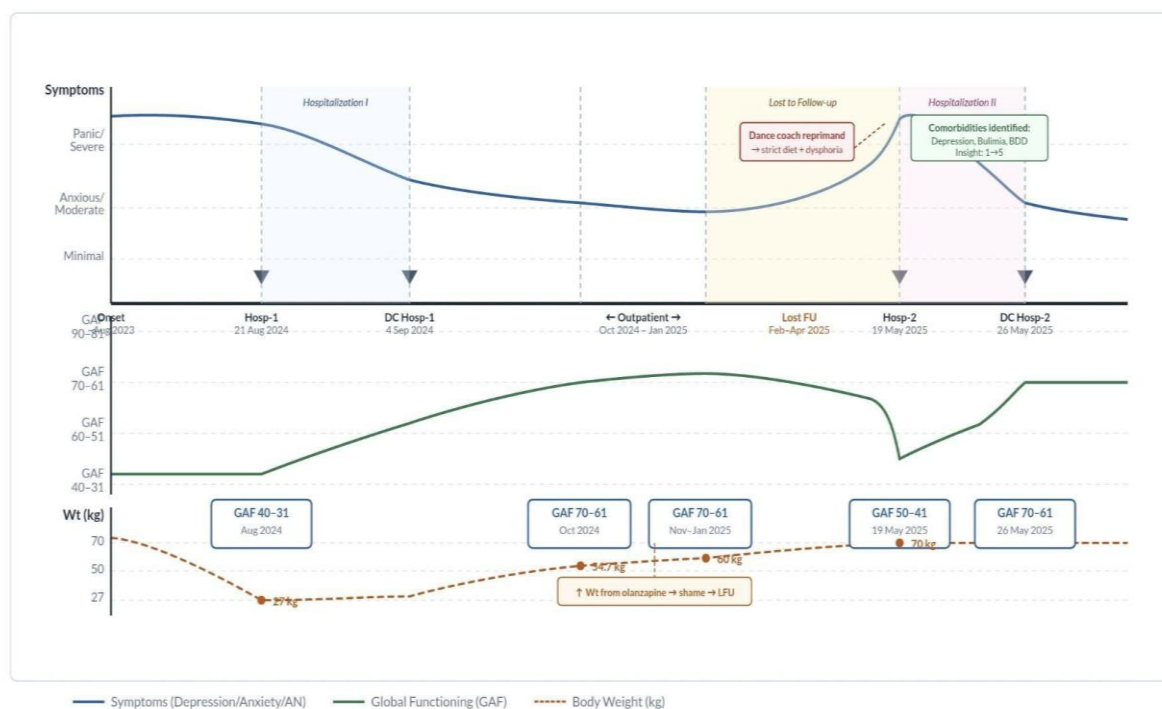
However, during a period of loss to follow-up, a psychosocial stressor triggered symptom exacerbation, leading to

maladaptive behaviors such as strict dietary restriction, along with worsening mood and sleep disturbance. This culminated in a relapse requiring a second inpatient admission, characterized by moderate-to-severe depressive symptoms and functional decline, despite adequate body weight.

During the second hospitalization, comorbid conditions were identified, and the patient showed clinical stabilization with treatment. At discharge, the patient achieved partial remission with improved global functioning (GAF 70–61), although residual symptoms persisted.

**Figure 1. Disease Course Chart**

Trajectory of symptoms, global functioning (GAF), and patient body weight – from onset to partial relapse



**Figure 1.** Shows the clinical trajectory of a 15-year-old girl with restricting-type anorexia nervosa and moderate depression. Symptom severity (blue), global functioning/ GAF (green), and body weight (orange dashed) changed over time, with improvement after the first hospitalization, worsening during loss to follow-up, and relapse requiring a second hospitalization. Although body weight increased, psychological symptoms and functioning did not improve consistently, indicating that physical recovery was not matched by full psychiatric recovery.

**Short-Term Outcome**

In the short term, the patient showed a favorable response to initial treatment, particularly after the first inpatient

admission. Acute symptoms decreased, eating behavior improved, and nutritional rehabilitation was achieved with significant weight gain from a severely underweight

baseline. Global functioning also improved from severe impairment (GAF 40–31) to a moderate level (GAF 70–61), with the patient resuming school and extracurricular activities. Nevertheless, residual anxiety and stress vulnerability persisted despite clinical stabilization.

### Medium-Term Outcome

In the medium term, the patient maintained partial remission with relatively stable functioning, as indicated by sustained GAF scores in the moderate-to-mild range. Weight restoration was maintained and exceeded expected targets. However, residual psychological distress remained, including social adjustment difficulties and affective symptoms. These findings indicate that physical recovery was not accompanied by full psychological recovery, and unresolved cognitive-emotional vulnerabilities continued to increase the risk of relapse.

### Relapse

Nine months after the initial hospitalization, the patient was rehospitalized due to a return of symptoms, which was assessed as an atypical anorexia nervosa. The relapse followed an incident in which her dance teacher reprimanded her publicly, urging her to lose weight in order to fit into a dance costume. The relapse was precipitated by a significant psychosocial stressor critical comment regarding body weight which led to strict dietary restriction, emotional distress, and sleep disturbance. This was followed by worsening depressive symptoms, including dysphoria, suicidal ideation, reduced intake, and social withdrawal, emerging during a loss-to-follow-up period. The condition progressed to functional decline and medical instability, requiring a second inpatient admission, despite adequate or excessive body weight, indicating a discordance between somatic and psychiatric recovery. Further evaluation revealed comorbid depressive disorder, bulimia nervosa, and body dysmorphic disorder, suggesting incomplete

management of the underlying psychopathology. After 7 days, the patient showed improvement and was discharged. Although partial remission was achieved after treatment, this course highlights the relapsing nature of eating disorders and the importance of long-term monitoring, psychosocial intervention, and relapse prevention.

### DISCUSSION

This case illustrates the complexity and challenges in managing restricting-type anorexia nervosa with a comorbidity of moderate depressive disorder, particularly in a female adolescent who experienced extreme weight loss. The severe weight loss, occurring over the course of one year, resulted from marked disordered eating behaviors, including strict calorie restriction and excessive physical activity. This is consistent with the diagnostic criteria for anorexia nervosa according to the DSM-5<sup>8</sup>: (a) Persistent restriction of energy intake relative to physiological needs, resulting in significantly low body weight when considering age, sex, developmental stage, and physical health status. Significantly low body weight refers to weight below the minimally normal range, or in children and adolescents, below the expected minimum. (b) Intense fear of gaining weight or becoming overweight, or ongoing behaviors that interfere with weight gain despite already having significantly low body weight. (c) Disturbance in the perception of body weight or shape, excessive influence of body weight or shape on self-evaluation, or persistent inability to recognize the seriousness of current low body weight.

The moderate depressive disorder was established based on the clinical symptoms observed in the patient, including loss of interest, fatigue, feeling of worthlessness or excessive guilt, impaired concentration, and the presence of suicidal ideation. These findings fulfill the diagnostic criteria outlined in the DSM-5<sup>8</sup> such as

depressed or irritable mood, loss of interest, significant weight change, sleep disturbance, psychomotor changes, fatigue, feelings of worthlessness or guilt, impaired concentration, or recurrent thoughts of death or suicide are present for a minimum of two weeks, cause significant impairment in social or occupational functioning, and are not attributable to substance use or another medical condition.

The re-emergence of psychiatric symptoms prior to the second hospital admission was diagnosed as atypical anorexia nervosa according to DSM-5<sup>8</sup>, in which all criteria for anorexia nervosa are met, except that, despite significant weight loss, the individual's body weight remains within or above the normal range. The current case presented with the following: comorbid depressive symptoms, additional medical treatment, short term (<1 year) of therapeutic contact, combination of in- and out-patient treatment (vs. only out-patient). These factors were found to significantly contribute to higher likelihood of relapse<sup>10,11</sup>. The differential diagnoses for this case include bulimia nervosa, obsessive-compulsive disorder, body dysmorphic disorder, and other medical conditions associated with weight loss (malabsorption syndromes and malignancy)<sup>8</sup>.

#### *Overall Treatment Recommendations*

The management of anorexia nervosa in adolescents should follow a multidisciplinary approach as recommended by National Institute for Health and Care Excellence (NICE) and National Health Service (NHS) guidelines, emphasizing psychological interventions as the cornerstone of treatment, alongside family involvement and careful physical monitoring. In line with these recommendations, psychological therapy was the primary modality in this case, with cognitive behavioral therapy (CBT) targeting cognitive distortions, emotional dysregulation, and maladaptive eating behaviors. Both guidelines support the use

of CBT, family-based therapy (FBT), adolescent-focused psychotherapy, and other structured psychological approaches for adolescents with anorexia nervosa. Notably, family interventions are recommended as first-line treatment for this population, and the active involvement of the patient's parents in enhancing emotional responsiveness and supportive communication represents a strong alignment with these standards<sup>12,13</sup>.

However, while guidelines recommend that outpatient psychological treatment should typically extend for at least six months or longer, the duration of CBT in this case was limited to three months, which may be partly explained by challenges in continuity of care. Consistent with both NICE and NHS recommendations, psychoeducation on balanced nutrition and weight restoration was incorporated, although dietary interventions alone are not considered sufficient without concurrent psychological therapy<sup>12,13</sup>.

Furthermore, pharmacological treatment is not recommended as a primary intervention for anorexia nervosa<sup>12,13</sup>. SSRIs and atypical antipsychotic medications (e.g., quetiapine, risperidone, and olanzapine) have shown limited effectiveness in promoting weight gain or improving eating-disorder symptoms. Current guidelines<sup>14</sup> approve the use of pharmacotherapy for comorbid conditions, such as depression and anxiety. Depression is the most common comorbid disorder of AN (lifetime comorbidity of 40–80%), followed by anxiety (20–60%), and OCD (20%)<sup>15</sup>. This patient presented with comorbid depressive symptoms. The treatment plan for the current case involved FBT alongside CBT, while antidepressants were also prescribed.

Overall, the treatment approach in this case demonstrates substantial alignment with established guidelines, particularly in prioritizing psychological and family-based interventions. The inclusion of

pharmacological treatment is also consistent with guideline recommendations, as it was appropriately used to address comorbid depressive symptoms rather than as a primary treatment for anorexia nervosa. Nonetheless, the shorter duration of therapy may be associated with challenges in continuity of care. By situating this case within established clinical guidelines, it becomes evident that combining family-based interventions with individual psychotherapy provides a more robust framework for treatment, particularly in adolescents where family dynamics play a central role. This integration also strengthens the clinical relevance of the psychodynamic findings, as it demonstrates how insight into internal conflicts and relational patterns can complement, rather than replace, evidence-based therapeutic approaches.

#### *Psychodynamics Aspects of AN*

Integrating psychodynamic perspective into treatment approaches may offer valuable insights into the emotional meaning of weight and eating behaviors, potentially reducing relapse and fostering more sustainable change. The relationship between childhood self-esteem and AN can be understood through psychodynamics, which emphasizes early life experiences, unconscious emotional conflicts, and familial dynamics in the development of ED.

Freud's classic psychoanalytic theory<sup>16</sup> focused on the internal conflict between id, ego, and superego. In this case, superego overpowered the ego. This is frequently observed in individuals with AN, reflecting an internal drive for perfection, a need for control, and an avoidance of id-driven gratification, such as eating. Early life adverse experiences may trigger a deep shame towards flaws or imperfections, which is then transformed into an obsession with body image, leading to intense efforts to attain physical perfection. For individuals with AN, achieving this ideal often brings a profound sense of pride<sup>17</sup>. In the presented

case, the patient received praise from her parents and peers when her body weight was low, reinforcing this sense of pride.

According to Freud's framework, individuals with AN and low self-esteem may develop defense mechanisms such as repression, introjection, and projection to manage anxiety<sup>16</sup>. Their self-worth becomes heavily dependent on body weight. In this case, dietary restriction and weight control symbolized power and self-worth, compensating for feelings of unworthiness and inadequacy in other areas of life rooted in childhood experiences.

Within psychodynamic theory, Winnicott<sup>18</sup> highlighted the crucial role of a supportive and nurturing environment in shaping a child's sense of identity. A secure and supportive environment is necessary to build a healthy self-esteem. When a parent is overcontrolling or unresponsive to the child's needs, the child may develop a defense mechanism that sacrifices the true self, resulting in what Winnicott described as the "False Self."

This case involved an adolescent girl with a distant father and an authoritarian mother. She was primarily cared for by her grandmother and a household assistant, while her mother worked long office hours and her father lived out of town, only returning on weekends. Her mother exhibited an authoritarian parenting style, often critical and demanding, while her father was passive and emotionally detached.

Adolescents with AN often present only their False Self, living for social and familial expectations instead of for themselves<sup>18</sup>. If a child feels accepted only when they are "perfect" (through performance or achievement), they may begin to suppress personal needs and emotions, leading to rigid control over diet and body as a way to construct a false sense of self-mastery or autonomy (reflecting the conflict between the True Self

and the False Self)<sup>18</sup>. This dynamic was evident in this case: before losing weight, the patient rarely received praise or attention from family and friends, whereas her weight loss was praised, encouraging her to continue. Over time, these behaviors intensified.

A mother's capacity to provide sufficient care and responsiveness in the early postnatal period is essential for fostering the emergence of a child's True Self. In this case, the patient developed a weak bond with her mother from early childhood, as her mother worked from morning until evening and rarely engaged in meaningful conversations. The patient interacted more frequently with her grandmother than with her parents. A child's self develops through specific experiences in maternal care that prevent disruption and preserve a sense of integration. This requires conditions such as physical support to promote wholeness, care that fosters respect and security, and guidance in engaging with the external world. If these conditions are not met, the child may develop a False Self.

Prior to admission and AN occurrence, the patient's BMI was classified as Obese Grade I. Research shows that up to one-third of adolescents with AN were previously overweight or obese<sup>19</sup>. Compared to those who had a normal weight history, adolescents with AN and a background of overweight or obesity were more likely to begin treatment at a normal BMI, despite having lost a greater percentage of body weight. This may explain our patient's relatively higher BMI during the occurrence of a partial relapse.

Furthermore, adolescents with a history of being overweight or obese reported experiencing more intense eating disorder symptoms, elevated levels of anxiety and depression, and a higher frequency of weight-related teasing by peers and weight-focused remarks from parents<sup>20</sup>. Of particular note, regardless of

prior weight status, such teasing is associated with greater severity of eating disorder symptoms, in addition to increased anxiety and depressive symptoms.

These social and psychological stressors can significantly influence body image, especially during adolescence, a crucial period for body image development due to the physical, psychological, and social changes that occur during this period<sup>21</sup>. Body image refers to the concept of a person's opinions, views, and feelings about their own body<sup>22</sup>, and is influenced by various external environments, including peers, parents, and media exposure. Adolescents tend to be highly aware of their own bodies, how they compare to those of their friends' and adults', and how it deviates from perceived social norms. This heightened self-awareness, especially when accompanied by negative or unkind comments, can harm adolescents' body image and self-concept<sup>23</sup>.

Such patterns reflect a broader phenomenon observed in young people, where weight stigma most commonly manifests as teasing or bullying based on body size, often referred to as body shaming. These experiences can be deeply damaging, resulting in long-lasting effects that negatively affect their emotional well-being and physical health over the course of their lives<sup>24</sup>. Childhood bullying, in particular, has been associated with a heightened risk of developing AN, while weight-related teasing has been linked to maladaptive behaviors such as emotional eating, eating in the absence of hunger, and negative attitudes toward food<sup>25</sup>.

Adolescents with obesity often face challenges in translating their inner experiences into symbolic forms and articulating internal struggles, which hindered their capacity to manage anxiety and instinctual urges. They may suppress impulses, remain psychologically dependent on authority figures, and display emotional underdevelopment that reflects a

wish to maintain childhood dependence<sup>26</sup>. This was noted from our patient, as she regarded her dance coach as a strict authority figure. The patient had always been worried about making mistakes during practices as she perceived her dance teacher as stern and assertive. Her symptoms also returned after her dance coach publicly berated her to lose weight, emphasizing the profound impact of external criticism on her emotional well-being.

#### *The Indonesian Context*

Negative body image is highly prevalent in high-, middle-, and low-income countries<sup>27</sup>. A study of body image in an Indonesian adolescent population showed that more than half of the girls did not have a high body esteem<sup>28</sup>. The study also reported a negative correlation between restrictive and avoidant eating behaviors and low body esteem.

To date, no nationwide research has been conducted in Indonesia on the prevalence of body shaming. However, existing studies in schools across different provinces suggest that body shaming is relatively common<sup>29-33</sup>, with moderate to high rates reported, which mirrors the global trends.

In Indonesia, sociocultural factors such as body image ideals, cultural norms, and social values strongly influence the risk of AN. Globalized beauty standards—reinforced by social media, Korean popular culture, and public figures—encourage the internalization of thinness, often leading to body dissatisfaction and disordered eating behaviors<sup>34</sup>. Within a collectivist society, cultural values emphasizing social harmony and family reputation can intensify pressure to maintain an “ideal” appearance, with weight-related comments from peers or family commonly normalized as concern. Body shaming has been shown to be significantly associated with anorexia tendencies among Indonesian adolescent girls<sup>35</sup>.

#### *Future Research in Indonesia*

Further research on the national prevalence of eating disorders is essential to determine whether the psychodynamic aspects observed in this case are unique to the individual or reflect broader trends among Indonesian adolescents. In addition, future studies should examine the role of sociocultural influences, including beauty ideals, social media exposure, collectivist family values, peer dynamics, and gender-specific appearance pressures in shaping the development of eating disorders

## **CONCLUSION**

Anorexia nervosa cases are rarely reported in Indonesia, making prevalence estimates difficult. From a psychodynamic perspective, AN reflects unresolved internal conflicts rooted in early attachment and family dynamics.

The formulation in this case highlights how childhood upbringing, self-worth, and sociocultural context contributed to the patient’s illness. Unresponsiveness from caregivers, particularly the mother, impeded the emergence of the True Self and fostered immature defense mechanisms. Regression emerged as the most prominent ego defense. Weak parental bonds and an authoritarian parenting style facilitated the development of a False Self. Strict dietary control functioned as pseudo-autonomy, compensating for perceived inadequacies in other areas of life. Praise for weight loss from family and peers reinforced restrictive behaviors, while a history of weight-related teasing worsened body image distortion. Finally, cultural norms emphasizing thinness, combined with collectivist values, intensified the pressure to maintain an ideal body image.

Management of adolescent anorexia nervosa should prioritize psychological interventions, with family-based treatment as first-line therapy, while pharmacotherapy may be used to address comorbid conditions such as depression. In this case,

a combined approach of family-based treatment, cognitive behavioral therapy, and antidepressants was implemented due to comorbid depressive symptoms. Overall, sustainable recovery requires not only symptom-focused treatment but also addressing the underlying emotional and relational dynamics that maintain the disorder.

This case underscores that sustainable recovery requires addressing the deeper emotional and relational issues underlying disordered eating, not just the symptoms.

### INFORMED CONSENT

This study employed an informed consent process, whereby the researchers were obligated to provide a comprehensive explanation of the study to the participants, ensuring that they fully understood its nature and voluntarily agreed to participate without any coercion.

### ETHICAL STATEMENT

The research proposal was submitted to the Medical and Health Research Ethics Committee of the Faculty of Medicine, Public Health, and Nursing, Universitas Gadjah Mada, to obtain ethical clearance.

### ACKNOWLEDGEMENTS

The authors would like to express their sincere gratitude to the patient for their courage and willingness to share their life experiences and treatment journey. This contribution is highly valuable for the preparation and development of this study. We would also like to express our sincere gratitude to the research assistants for their valuable contributions to the completion of this study. We also acknowledge the multidisciplinary medical team for their professional care and clinical input. This case report is presented for academic and educational purposes, and all patient information has been anonymized to protect confidentiality.

### REFERENCES

1. Moore CA, Bokor BR. Anorexia Nervosa [Internet]. Treasure Island (FL): StatPearls Publishing; 2023. Available from: <https://www.ncbi.nlm.nih.gov/books/NBK459148/>
2. Wallin K, Wallin U, Wentz E, Råstam M, Johnsson P. A comparison between young males and females with anorexia nervosa in a clinical setting. *Nord J Psychiatry*. 2023 Jan 3;77(1):91–5.
3. Alharbi Y, Saleh F, Shahat KA. Effective Treatment Approaches for Eating Disorders in Children and Adolescents: A Review Article. *Cureus* [Internet]. 2024 Nov 19 [cited 2025 Aug 6]; Available from: <https://www.cureus.com/articles/28390-1-effective-treatment-approaches-for-eating-disorders-in-children-and-adolescents-a-review-article>
4. Liu K, Gao R, Kuang H, E R, Zhang C, Guo X. Global, regional, and national burdens of eating disorder in adolescents and young adults aged 10–24 years from 1990 to 2021: A trend analysis. *J Affect Disord*. 2025 Nov;388:119596.
5. Chen Q, Huang S, Peng JY, Xu H, Wang P, Shi XM, et al. Trends and prevalence of eating disorders in children and adolescents. *World J Psychiatry*. 2024 Dec 19;14(12):1815–26.
6. Tantiani T, Syafiq A. Perilaku Makan Menyimpang pada Remaja di Jakarta. *Kesmas Natl Public Health J*. 2008 June 1;2(6):255.
7. Syah MuhNH, Asna AF. Risiko Gangguan Makan dan Kejadian Anemia pada Mahasiswa Putri Program Studi S1 Gizi STIKES Mitra Keluarga. *Ghidza J Gizi Dan Kesehatan*. 2020 June 16;2(1):1–6.
8. American Psychiatric Association. *Diagnostic and Statistical Manual of*

- Mental Disorders [Internet]. Fifth Edition. American Psychiatric Association; 2013 [cited 2025 Aug 12]. Available from: <https://psychiatryonline.org/doi/book/10.1176/appi.books.9780890425596>
9. Khalsa SS, Portnoff LC, McCurdy-McKinnon D, Feusner JD. What happens after treatment? A systematic review of relapse, remission, and recovery in anorexia nervosa. *J Eat Disord*. 2017 Dec;5(1):20.
  10. Berends T, Boonstra N, Van Elburg A. Relapse in anorexia nervosa: a systematic review and meta-analysis. *Curr Opin Psychiatry*. 2018 Nov;31(6):445–55.
  11. Sala M, Keshishian A, Song S, Moskowitz R, Bulik CM, Roos CR, et al. Predictors of relapse in eating disorders: A meta-analysis. *J Psychiatr Res*. 2023 Feb;158:281–99.
  12. National Institute for Clinical Excellence. *Eating disorders: core interventions in the treatment and management of anorexia nervosa, bulimia nervosa and related eating disorders* [Internet]. London: NICE; 2004 [cited 2026 Apr 7]. Available from: <http://www.nice.org.uk/CG9>
  13. NICE Guideline. Eating disorders: recognition and treatment (NG69) [Internet]. National Institute for Health and Care Excellence; 2017. Available from: <https://www.nice.org.uk/guidance/ng69/chapter/Recommendations>
  14. Bohon C, Le Grange D, Attia E, Golden NH, Steinberg D. United States-based practice guidelines for children and adolescents with eating disorders: Synthesis of clinical practice guidelines. *J Eat Disord*. 2025 Apr 11;13(1):66.
  15. Herpertz S, De Zwaan M, Zipfel S, editors. *Handbook of Eating Disorders and Obesity* [Internet]. Berlin, Heidelberg: Springer Berlin Heidelberg; 2024 [cited 2025 Aug 6]. Available from: <https://link.springer.com/10.1007/978-3-662-67662-2>
  16. Zhang S. Psychoanalysis: The Influence of Freud's Theory in Personality Psychology: In Wuhan, China; 2020 [cited 2025 Aug 5]. Available from: <https://www.atlantispress.com/article/125939185>
  17. Howard TLM, Williams MO, Woodward D, Fox JRE. The relationship between shame, perfectionism and Anorexia Nervosa: A grounded theory study. *Psychol Psychother Theory Res Pract*. 2023 Mar;96(1):40–55.
  18. Ehrlich R. Winnicott's Idea OF The False Self: Theory as Autobiography. *J Am Psychoanal Assoc*. 2021 Feb;69(1):75–108.
  19. Lebow J, Sim LA, Kransdorf LN. Prevalence of a History of Overweight and Obesity in Adolescents With Restrictive Eating Disorders. *J Adolesc Health*. 2015 Jan;56(1):19–24.
  20. Matthews A, Kramer RA, Mitan L. Eating disorder severity and psychological morbidity in adolescents with anorexia nervosa or atypical anorexia nervosa and premorbid overweight/obesity. *Eat Weight Disord - Stud Anorex Bulim Obes*. 2022 Feb;27(1):233–42.
  21. Lacroix E, Smith AJ, Husain IA, Orth U, Von Ranson KM. Normative body image development: A longitudinal meta-analysis of mean-level change. *Body Image*. 2023 June;45:238–64.
  22. Thompson JK, Heinberg LJ, Altabe M, Tantleff-Dunn S. *Exacting beauty: Theory, assessment, and treatment of body image disturbance*. [Internet]. Washington, DC: American Psychological Association; 1999 [cited 2025 Aug 12]. Available from: <https://content.apa.org/books/10312-000>
  23. Wong DL. Wong's nursing care of

- infants and children. 11th edition. Hockenberry MJ, Wilson D, Rodgers CC, editors. St. Louis, Missouri: Mosby; 2019.
24. Puhl RM, Lessard LM. Weight Stigma in Youth: Prevalence, Consequences, and Considerations for Clinical Practice. *Curr Obes Rep.* 2020 Dec;9(4):402–11.
  25. Barakat S, McLean SA, Bryant E, Le A, Marks P, National Eating Disorder Research Consortium, et al. Risk factors for eating disorders: findings from a rapid review. *J Eat Disord.* 2023 Jan 17;11(1):8.
  26. Antonio LR, Barbieri V. PSYCHODYNAMICS OF OBESE ADOLESCENTS IN THE THEMATIC APPERCEPTION TEST (TAT) – PARISIAN SCHOOL. *Psicol Clínica.* 2022;34(3):509–30.
  27. Al Sabbah H, Vereecken CA, Elgar FJ, Nansel T, Aasvee K, Abdeen Z, et al. Body weight dissatisfaction and communication with parents among adolescents in 24 countries: international cross-sectional survey. *BMC Public Health.* 2009 Dec;9(1):52.
  28. Garbett KM, Craddock N, Saraswati LA, Diedrichs PC. Body Image among Girls in Indonesia: Associations with Disordered Eating Behaviors, Life Engagement, Desire for Cosmetic Surgery and Psychosocial Influences. *Int J Environ Res Public Health.* 2023 July 19;20(14):6394.
  29. Deviantony F, Fitria Y, Rondhianto R, Pramesuari NKT. An in depth review of body shaming phenomenon among adolescent: Trigger factors, psychological impact and prevention efforts. *South Afr J Psychiatry* [Internet]. 2024 Nov 14 [cited 2025 Aug 15];30. Available from: <https://sajp.org.za/index.php/sajp/article/view/2341>
  30. Oktiany T. Konsep Diri Pada Remaja Dengan Body Shaming Di SMP Negeri 3 Gunung Jati Kabupaten Cirebon. *Blantika Multidiscip J.* 2023 May 11;2(2):166–73.
  31. Alini A, Meisyalla LN. GAMBARAN KEJADIAN BODY SHAMING DAN KONSEP DIRI PADA REMAJA DI SMKN 1 KUOK. *PREPOTIF J Kesehat Masy.* 2021 Oct 28;5(2):1170–9.
  32. Intan AS. Hubungan Antara Body Shaming Dan Citra Diri Dengan Kecemasan Sosial Pada Siswa SMP Ekasakti Semarang. *JCOSE J Bimbing Dan Konseling.* 2021 Mar 24;3(1):22–33.
  33. Hariyati R, Setiawan MA, Sulistiyana S. The effect of body shaming on students who blame themselves. *KONSELI J Bimbing Dan Konseling E-J.* 2022 Nov 30;9(2):149–56.
  34. Sulistyan A, Huryati E, Hastuti J. Distorsi citra tubuh, perilaku makan, dan fad diets pada remaja putri di Yogyakarta. *J Gizi Klin Indones.* 2016;12(3):99–107.
  35. Sari TI, Rosyidah R. Pengaruh Body Shaming terhadap Kecenderungan Anorexia Nervosa pada Remaja Perempuan di Surabaya. *Pers J Ilmu Psikol.* 2020 Nov 27;11(2):202–17.