



Published by IJBNR

# THE EFFECT OF SHAKER EXERCISE AND EFFORTFUL SWALLOW ON CHANGES IN THE DEGREE OF DYSPHAGIA IN PATIENTS WITH STROKE: CASE STUDY



Cross Mark

Rina Audina<sup>\*</sup>, Arif Setyo Upoyo, Agis Taufik  
Department of Nursing, Faculty of Health Sciences, Jenderal Soedirman University

## ABSTRACT

**Introduction:** Stroke can cause various kinds of complications. One of the complications of stroke is dysphagia. Therefore, dysphagia management is necessary for stroke patients with dysphagia. Dysphagia management can be done by screening stroke patients with dysphagia and carrying out swallowing therapy with shaker exercise and effortful swallow. **Purpose:** This case study aims to evaluate the effect of shaker exercise and effortful swallowing on changes in the degree of dysphagia in patients with stroke. **Methods:** The method used is case study analysis based on nursing intervention with description analysis. The sample used was a dysphagia patient with a stroke. The instrument used to measure the degree of dysphagia is the Gugging Swallowing Screen (GUSS). **Discussion:** After the shaker exercise and effortful swallow intervention for 5 consecutive days in the morning and evening, there was a change in the degree of dysphagia from initially getting 4 which means a severe degree of dysphagia with a high risk of aspiration to 18 which means mild dysphagia with a low risk of aspiration. **Conclusion:** Shaker exercise and effortful swallowing can improve the degree of dysphagia in stroke patients.

**Keywords:** Dysphagia, effortful swallow, shaker exercise

**Citation:** Audina, R., Upoyo, A. S. & Taufik, A. 2025. 'The Effect of Shaker Exercise and Effortful Swallow on Changes in The Degree of Dysphagia in Patients with Stroke: Case Study'. *International Journal of Biomedical Nursing Review*. 4(1). p16-21. <https://doi.org/10.20884/1.ijbnr.2025.4.1.10633>

## INTRODUCTION

Stroke is the main cause of long-term disability and is the second leading cause of death in the world after heart disease (Yang et al., 2023). Apart from being a cause of death, stroke is a cause of disability. Someone who has had a stroke will be a significant risk factor for recurrent stroke (Chohan, Venkatesh & How, 2019).

Stroke can cause various kinds of complications. One of the complications resulting from stroke is dysphagia. The chance of dysphagia in patients with stroke is around 8.1% to 45.3%. Dysphagia can affect more than 50% of stroke patients' future conditions. Dysphagia can increase complications and worsen post-stroke patient conditions such as pneumonia. Nutritional disorders and dehydration can also appear as complications of dysphagia, thereby reducing the quality of life of

stroke patients (Bond et al., 2023).

Dysphagia management is needed for stroke patients with dysphagia aimed at preventing and minimizing swallowing difficulties in stroke patients. Dysphagia management can be done by screening stroke patients with dysphagia and carrying out swallowing therapy with shaker exercise and effortful swallow (Gao et al., 2023; Gomes, 2022). Shaker exercise is a type of swallowing therapy that functions to improve swallowing ability, prevent aspiration and increase oral intake in stroke patients (Adel Ebada El Sayed & Mohamed Khalifa Ewees, 2020). Apart from shaker exercise, swallowing therapy can also be done with Effortful Swallow therapy. Effortful Swallow is one way to train throat muscle contractions by swallowing as hard as possible and then pushing the tongue towards the roof of the mouth when swallowing (Gomes, 2022).

\* Correspondence Author:  
Rina Audina;  
Department of Nursing,  
Faculty of Health Sciences,  
Jenderal Soedirman  
University, Purwokerto,  
Indonesia  
[audinarina05@gmail.com](mailto:audinarina05@gmail.com)

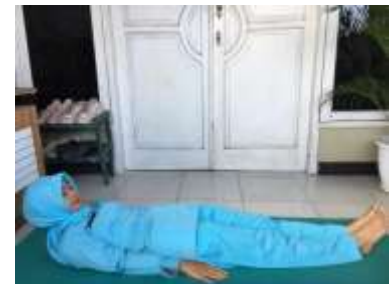Received: 13-12-2023  
Approved: 20-12-2024  
Published: 31-01-2025

Based on the description above, the author is interested in implementing shaker exercise and effortful swallow in dysphagia patients with stroke to improve swallowing ability by looking at changes in the degree of dysphagia in stroke patients in the hospital.

### METHOD

The method used is case study analysis based on nursing intervention with description analysis. The sample used was a dysphagia patient with a stroke. The stages carried out are (1) raising questions (PICO) (2) looking for related evidence (3) assessing the evidence based (4) implementing evidence based (5) evaluating the implementation of EBN (Polit & Beck, 2012).

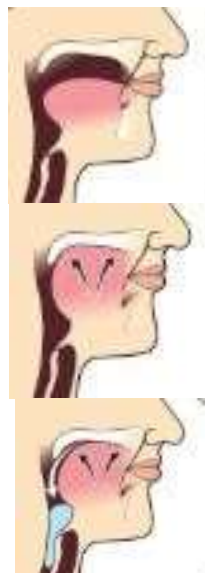Shaker exercise and effortful swallow on patients by carrying out direct demonstrations and practice for 5 consecutive days every morning and evening and evaluation is carried out every day using the Gungging Swallowing Screen (GUSS) to measure the degree of dysphagia. The steps carried out in the shaker exercise include isometric and isotonic exercises. Isometric exercises are carried out by flexing the head, namely the movement of lifting the head to look at the toes without lifting the shoulders for 60 seconds, followed by resting (returning to a lying position) for 60 seconds. This isometric exercise is repeated three times. This is followed by isotonic exercises, namely doing thirty repetitions of alternating upward and downward head movements.



**Image of shaker exercise movement**

Meanwhile, the steps taken in effortful swallowing are by pressing the tongue as hard as possible towards the roof of the

mouth and then swallowing as hard as the patient can. Effortful swallow is done 10 times per exercise.



Stage 1: start with the tongue position as usual

Stage 2: press the tongue as hard as possible towards the roof of the mouth according to ability

Stage 3: swallow as hard as you can

**Source: University Hospitals Coventry and Warwickshire (2020)**

## RESULT

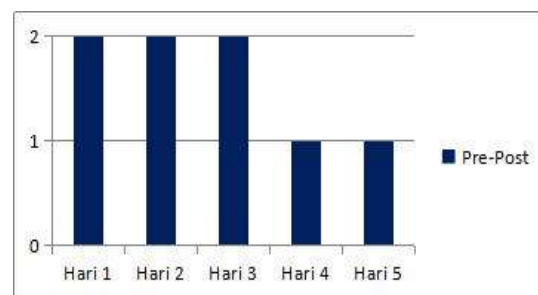
### Case Report

The client complained of weakness in the left area of movement. The client seems to be drooling without the client realized. The client also said that he was unable to control the saliva that came out of his mouth. The client as difficulty eating or drinking. The client said that he often coughs and chokes when eating or drinking. Thus, the client feeds food little by little or in small sizes. The client said his appetite had decreased, so client could only eat approximately 3 tablespoons at each meal. The results of screening for swallowing disorders using gugging swallowing screening showed that the client received a score of 4, which means severe dysphagia with a high risk of aspiration. All of the client's daily needs are completely assisted by his wife or waiting family. The client also complained of dizziness and couldn't sleep because he heard noises from the room next to the client.

Orientation the client is quite good, the client can communicate, and answer questions asked, but sometimes client suddenly cut off the conversation and diverts to another topic that is less relevant to the topic being discussed. The results of the examination showed blood pressure: 152/115 mmHg, pulse: 97x/minute, RR: 20x/minute, temperature: 36.5 °C, SpO<sub>2</sub>: 99% (NK 3 liter/minute). During the assessment Client looked weak, sweaty and had a pale face. Slightly dirty hair looks oily and black, there are no lumps, and no tenderness. Both eyes are symmetrical, and clean, the eyeballs are not protruding, the sclera is not icteric, conjunctiva is anemic. The nose looks symmetrical, there is no discharge, no dirt, and no obstruction, 3 liter/minute nasal cannula is installed. Both ears are symmetrical, with no cerumen and no tenderness. The mouth appears to be drooling. During lung inspection, there were no chest retractions, and no surgical scars. On percussion: there is no organ swelling. On palpation: normal tactile fremitus, as well as vesicular lung sounds. During cardiac inspection, there were no chest retractions, and no surgical scars. At

the time of percussion, there was no swelling of the organs in the heart. On palpation, there was no tenderness, and the S1 and S2 heart sounds were regular. There are no surgical scars in the abdominal area, bloating, bowel sounds 12x/minute, tympanic sounds, and no swelling of organs in the abdominal area. The acral extremities feel warm, there is no edema, CRT: < 3 seconds, the right upper and lower extremities can move freely without assistance in fighting gravity, while the left upper and lower extremities have no muscle contractions at all and cannot be moved. Based on the data analysis carried out, the nursing problem is swallowing disorders et causa cerebrovascular disorders (D. 0063).

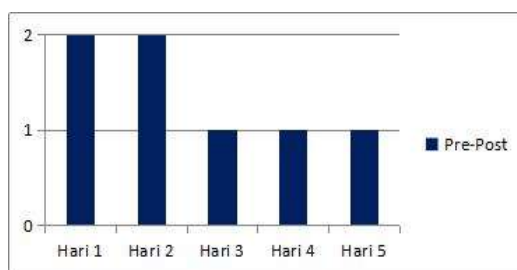
The intervention given by the diagnosis made is by providing a combination of shaker exercise and effortful swallowing. These two exercises are measures to improve swallowing ability in patients with dysphagia or swallowing disorders. The aim of the shaker exercise and effortful swallow intervention for 5 days is expected to improve swallowing status with the criteria that coughing and the frequency of choking are quite reduced, and saliva production improves.



**Grafik 1:** The incidence of coughing before and after implementing shaker exercise and effortful swallow

Information:

- 1: No coughing
- 2: Cough

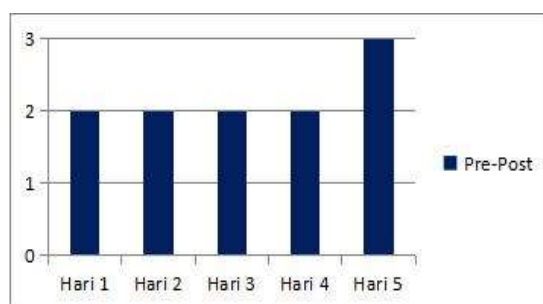


**Grafik 2.** Excretion of saliva before and after implementing the shaker exercise and effortful swallow

Information:

1: No Drooling

2: Drooling



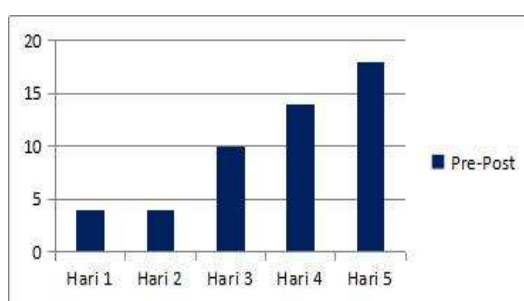
**Grafik 3.** The ability to swallow before and after implementing the shaker exercise and effortful swallow

Information:

1: Can't swallow

2: Delayed swallowing (>2 seconds and >10 seconds solid textured)

3: Able to swallow



**Grafik 4.** Degree of dysphagia before and after implementation of shaker exercise and effortful swallow

Information:

0-9: severe dysphagia with high risk of aspiration

10-14: moderate dysphagia with risk of aspiration

15-19: mild dysphagia with low risk of aspiration

20: no dysphagia with low risk of

aspiration

The results of the nursing evaluation were obtained after implementing shaker exercise and effortful swallow for 5 days. The patient's degree of dysphagia improved from initially getting a score of 4 (severe dysphagia with a high risk of aspiration) to a score of 18 (mild dysphagia with a low risk of aspiration).

## DISCUSSION

The results of this case study show that after implementing the shaker exercise and effortful swallow for 5 days, the degree of dysphagia gradually improved every day, from previously having a severe degree of dysphagia with a high risk of aspiration (score 4) to a mild degree of dysphagia with a low risk of aspiration (score 18). Apart from this, the patient also said that coughing and choking no longer occurred when the patient consumed liquids or other foods. Initially, the patient was unable to control and realize the release of saliva. After doing the shaker exercise and effortful swallowing, the patient was able to control it and no more unconscious saliva production occurred. Shaker exercise is a form of rehabilitation that aims to improve the ability of the suprahyoid muscles in the neck which, when swallowing, play a role in increasing the upward and forward movement of the hyoid bone and larynx so that the opening of the esophageal muscle sphincter increases. An increase in the opening of the sphincter muscle will make it easier for food to enter the lower digestive tract (Tarihoran, 2019). Meanwhile, an effortful swallow trains the muscles, especially the mouth and pharynx. The oral cavity muscles in question are the Base of the tongue (BOT) or lower part of the tongue and the pharynx, namely the posterior pharyngeal

wall. By training these muscles, you can increase higher pressure in the pharynx area, thereby reducing food residue in the oral cavity area (Bahia & Lowell, 2020).

The improvement in the degree of dysphagia meant that food intake increased quite a bit from initially only 3 tablespoons for 1 meal to half a portion for 1 meal on



the 5th day of intervention. This happened because the patient's ability to swallow increased after the shaker exercise and effortful swallow intervention. The results of this case study are by the research of Winandari et al., (2022) who explained that shaker exercise can improve the adequacy of nutritional status because it reduces the risk of aspiration due to dysphagia. American Speech Language Hearing Association in Hariati, Rizani & Marwansyah (2022), explained that carrying out swallowing exercises by pushing the tongue as hard as possible towards the palate, it can increase the movement of the posterior base of the tongue which can facilitate bolus clearance.

## CONCLUSION

After implementing shaker exercise and effortful swallowing in dysphagia patients with stroke, there was a change in the degree of dysphagia. On the first day before implementation, the degree of dysphagia was measured using a gugging swallowing screen with a score of 4, which means the patient was in the category of severe dysphagia with a high risk of aspiration. Meanwhile, after implementation for 5 days, the degree of dysphagia was measured again with a score of 18, which means the patient was in the mild dysphagia category with a low risk of aspiration.

## REFERENCES

- Adel Ebada El Sayed, R. & Mohamed Khalifa Ewees, A. 2020, 'Effect of Shaker Exercise on Dysphagia Level among Patients with Cerebral Vascular Stroke', *Egyptian Journal of Health Care*, vol. 11, no. 1, pp. 477–90.
- Bahia, M.M. & Lowell, S.Y. 2020, 'A systematic review of the physiological effects of the effortful swallow maneuver in adults with normal and disordered swallowing', *American Journal of Speech-Language Pathology*, vol. 29, no. 3, pp. 1655–73.
- Bond, V., Doeltgen, S., Kleinig, T. & Murray, J. 2023, 'Dysphagia-Related Acute Stroke Complications: A Retrospective Observational Cohort Study', *Journal of Stroke and Cerebrovascular Diseases*, vol. 32, no. 6, pp. 1–8.
- Chohan, S.A., Venkatesh, P.K. & How, C.H. 2019, 'Long-term complications of stroke and secondary prevention: An overview for primary care physicians', *Singapore Medical Journal*, vol. 60, no. 12, pp. 616–20.
- Gao, M., Xu, L., Wang, X., Yang, X., Wang, Y., Wang, H., Song, J. & Zhou, F. 2023, 'Efficacy and safety of oropharyngeal muscle strength training on poststroke oropharyngeal dysphagia: a systematic review and meta-analysis', *BMJ open*, vol. 13, no. 9, pp. 1–10.
- Gomes, A. 2022, 'Swallowing Exercises', *UHN Toronto*, pp. 1–8.
- Hariati, N., Rizani, A. & Marwansyah 2022, 'Pengaruh Effortful Swallow Terhadap Intake Nutrisi pada Pasien Stroke dengan Disfagia', *Jurnal Citra Keperawatan*, vol. 10, no. 2, pp. 102–8.
- Polit & Beck 2012, *Resource Manual for Nursing Research. Generating and Assessing Evidence for Nursing Practice*, 9th edn, Lippincott, USA.
- Tarihoran, Y. 2019, 'Pengaruh Shaker Exercise terhadap Kemampuan Menelekan pada Pasien Stroke dengan Disfagia di Rumah Sakit Kota Medan', *Indonesian Trust Health Journal*, vol. 1, no. 2, pp. 61–7.
- Winandari, F., Ismoyowati, T.W., Nugraha, C.T., Wahyuning, L.E. & Rosari, M.R. 2022, 'Efektifitas Shaker Exercise terhadap Disfagia pada Pasien Stroke: The Integrative Literature Review', *Jurnal Penelitian Kesehatan Suara Forikes*, vol. 13, no. 2, pp. 290–7.
- Yang, M., Yoo, H., Kim, S.Y., Kwon, O., Nam, M.W., Pan, K.H. & Kang, M.Y. 2023, 'Occupational Risk Factors for Stroke: A Comprehensive Review', *Journal of Stroke*, vol. 25, no. 3, pp. 327–37.



This work is licensed under a Creative Commons Attribution